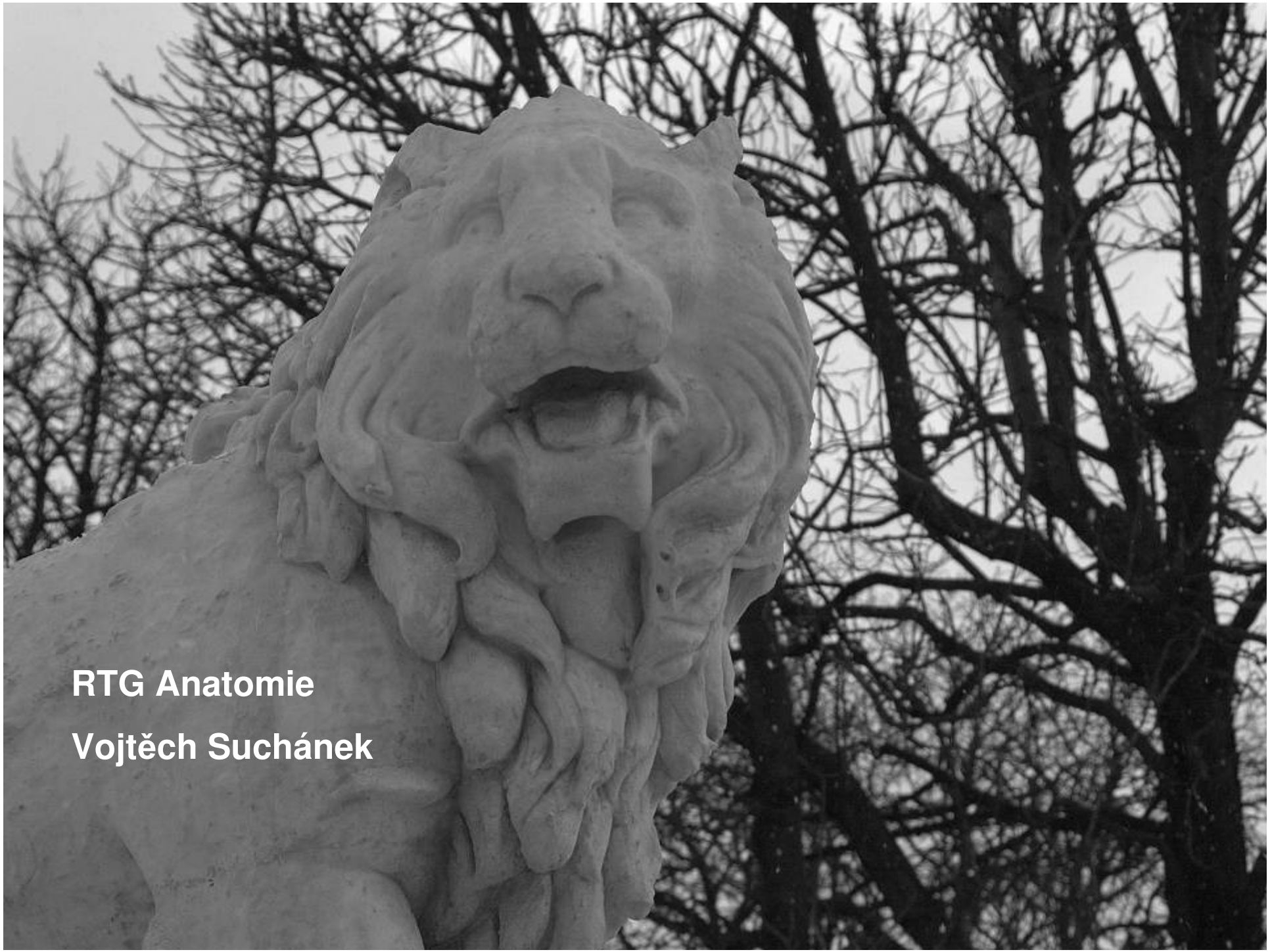

RTG Anatomie

Vojtěch Suchánek

Anatomické knihy





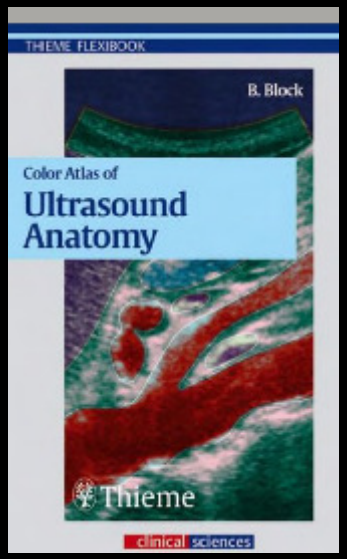

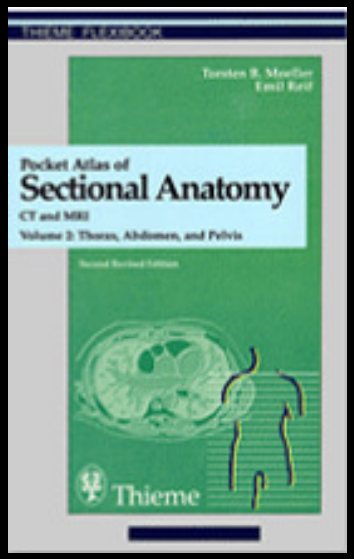

Dx
Sin

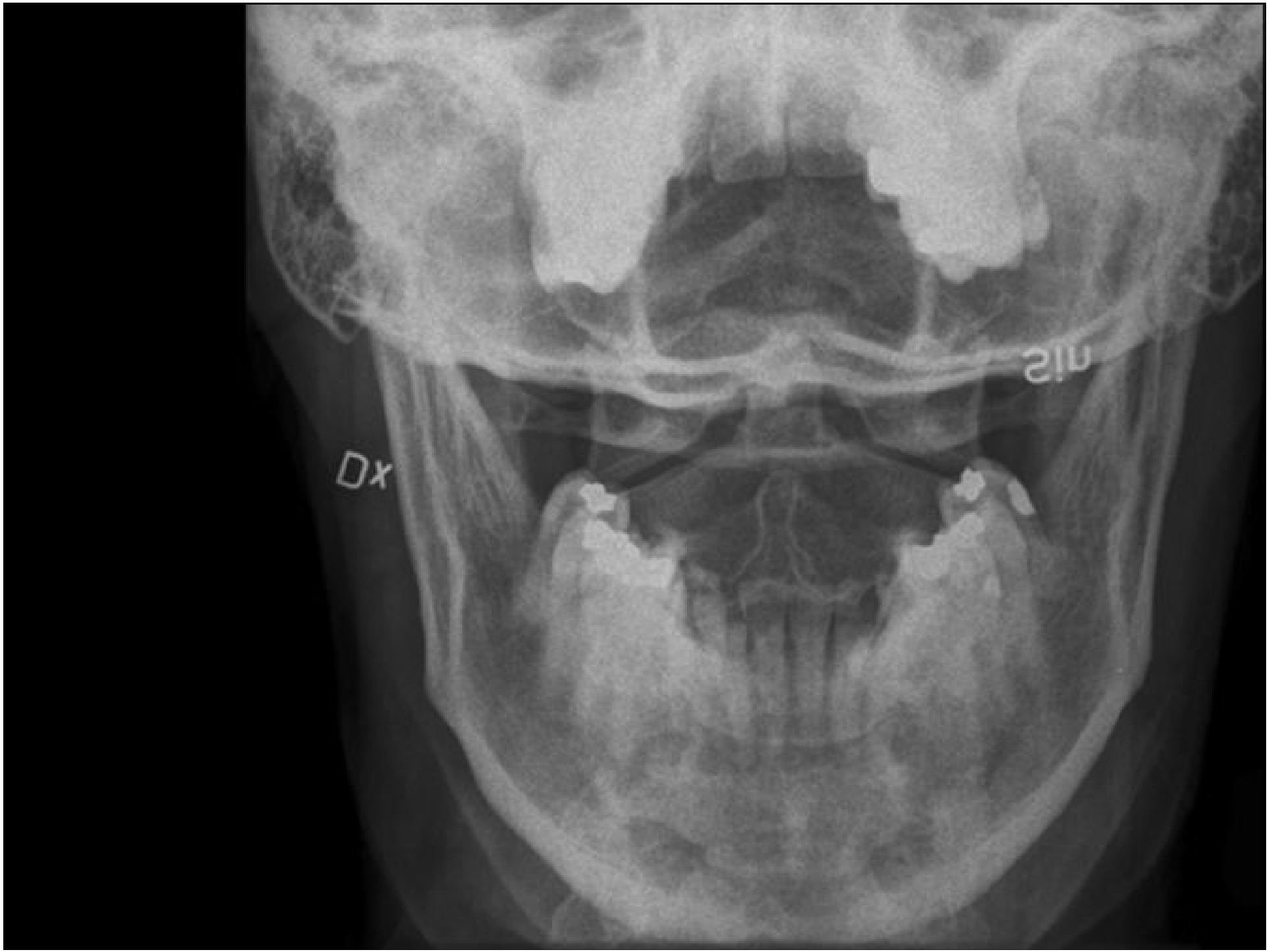
Dx
Sin

Dx

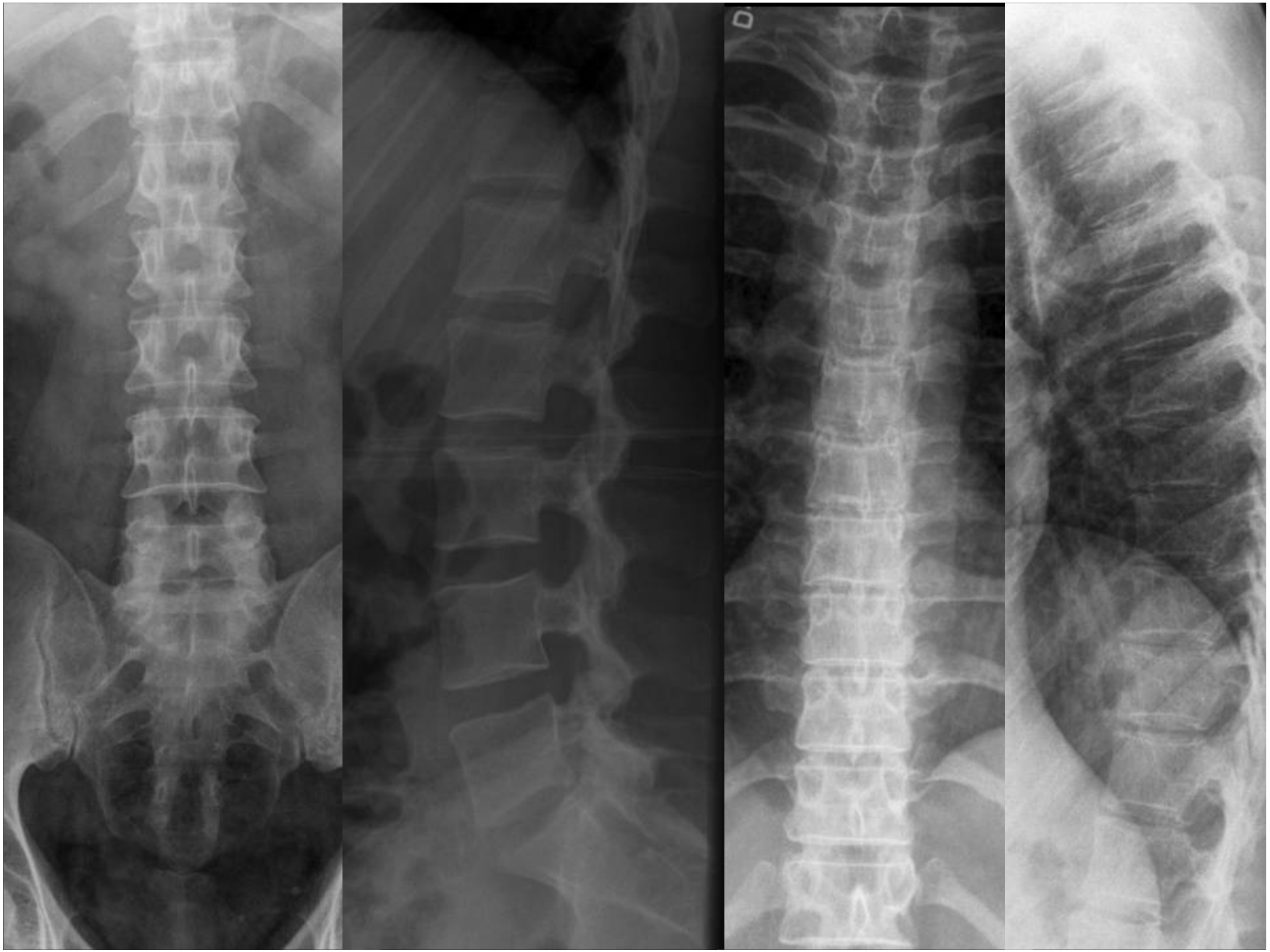

RTG hrudníku



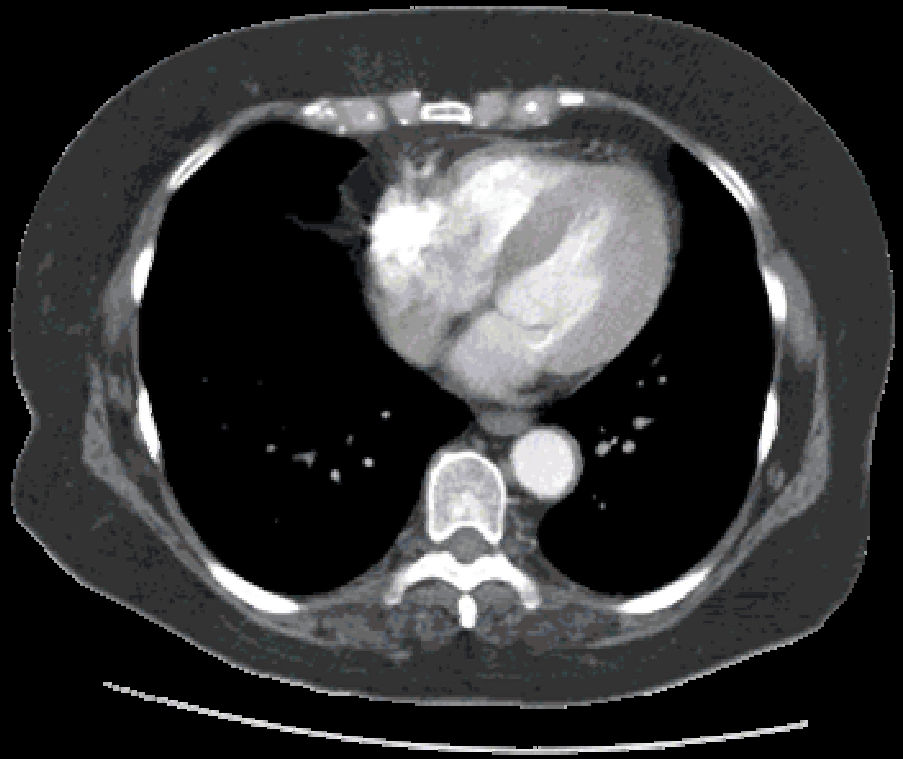

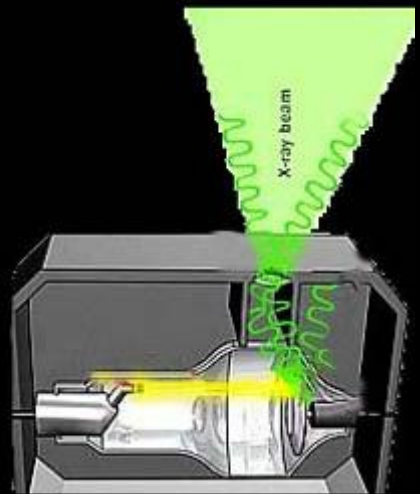
X-ray beam

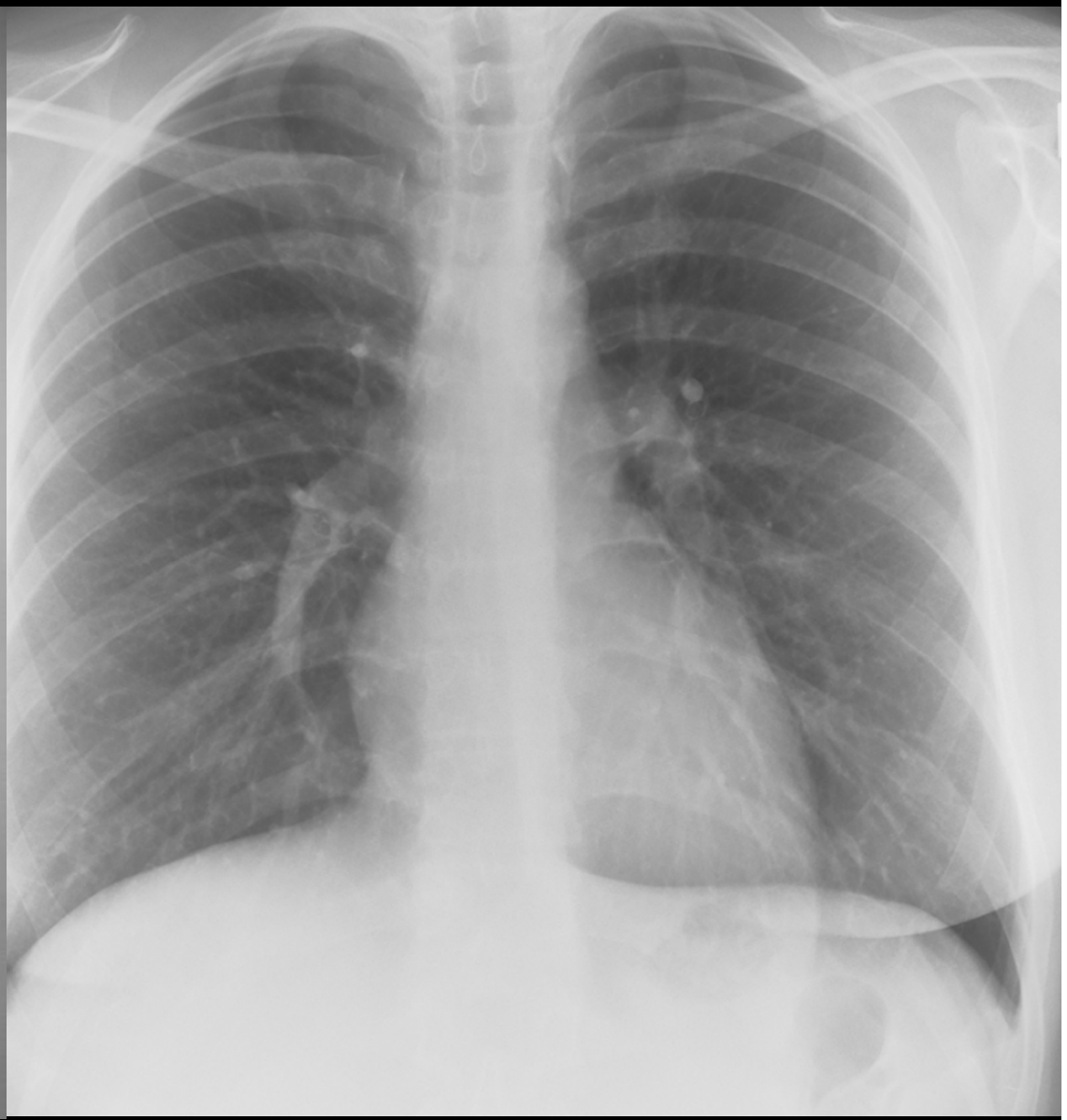

Anatomie

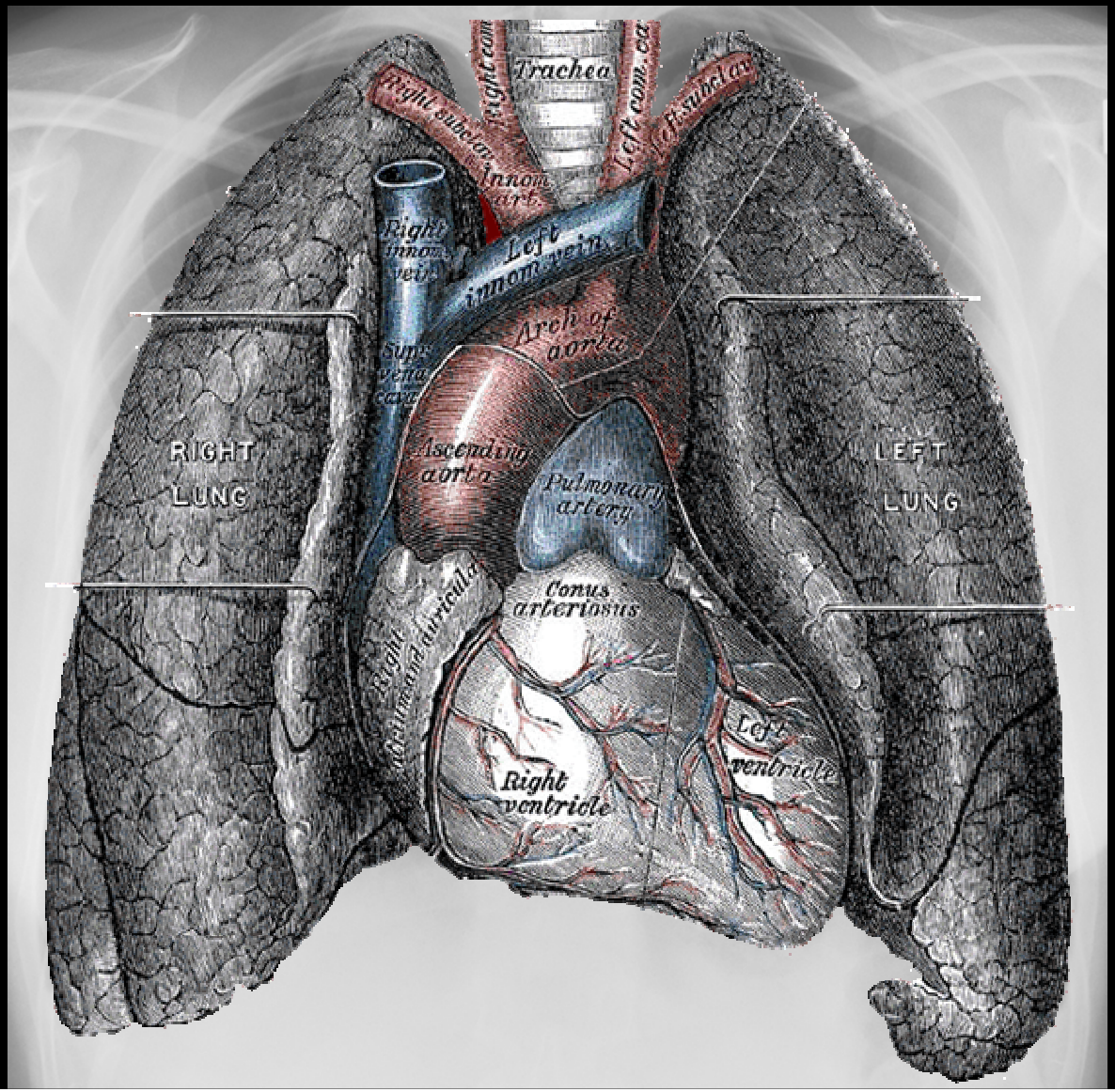
Trachea
Right com. ca.
Left com. ca.
Right subclav.
L. subclav.
Innom. art.
Right innom. vein
Left innom. vein
Arch of aorta
Sup. vena cava
Ascending aorta
Pulmonary artery
Conus arteriosus
Right auricle and auricula
Right ventricle
Left ventricle
RIGHT LUNG
LEFT LUNG

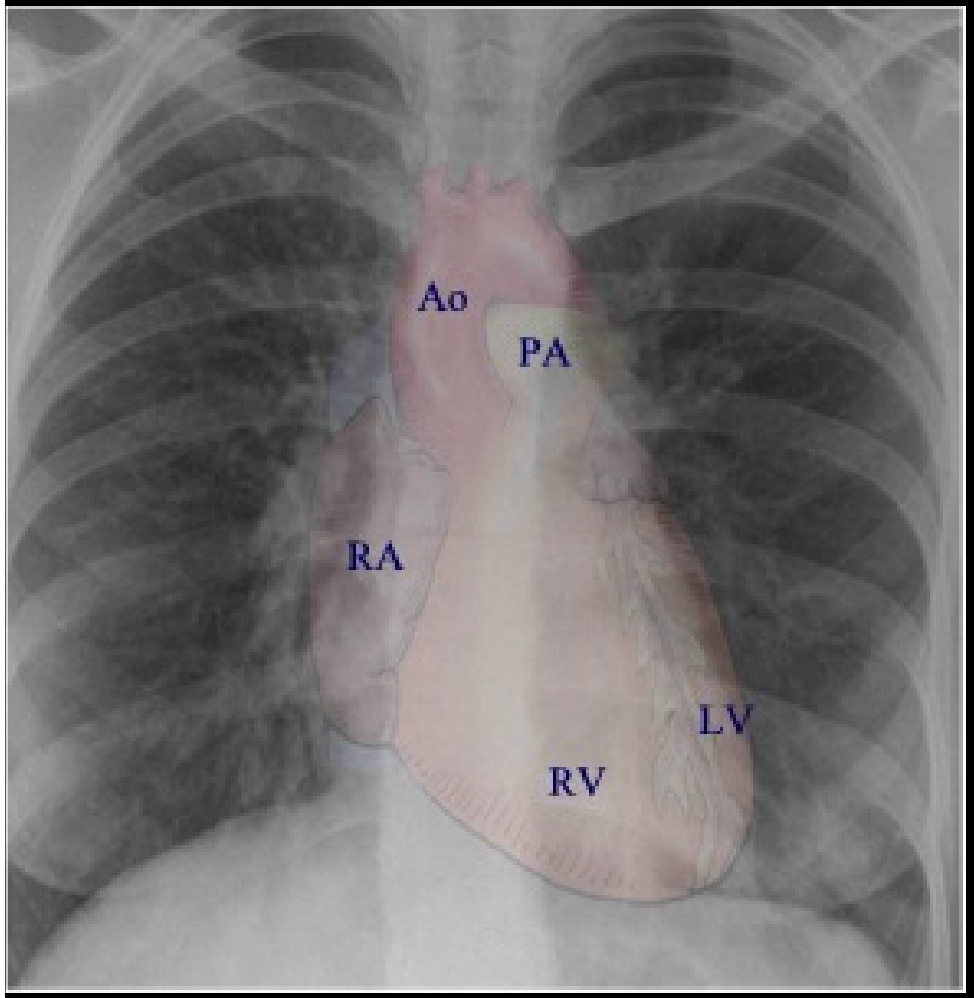
Ao
PA
RA
LV
RV

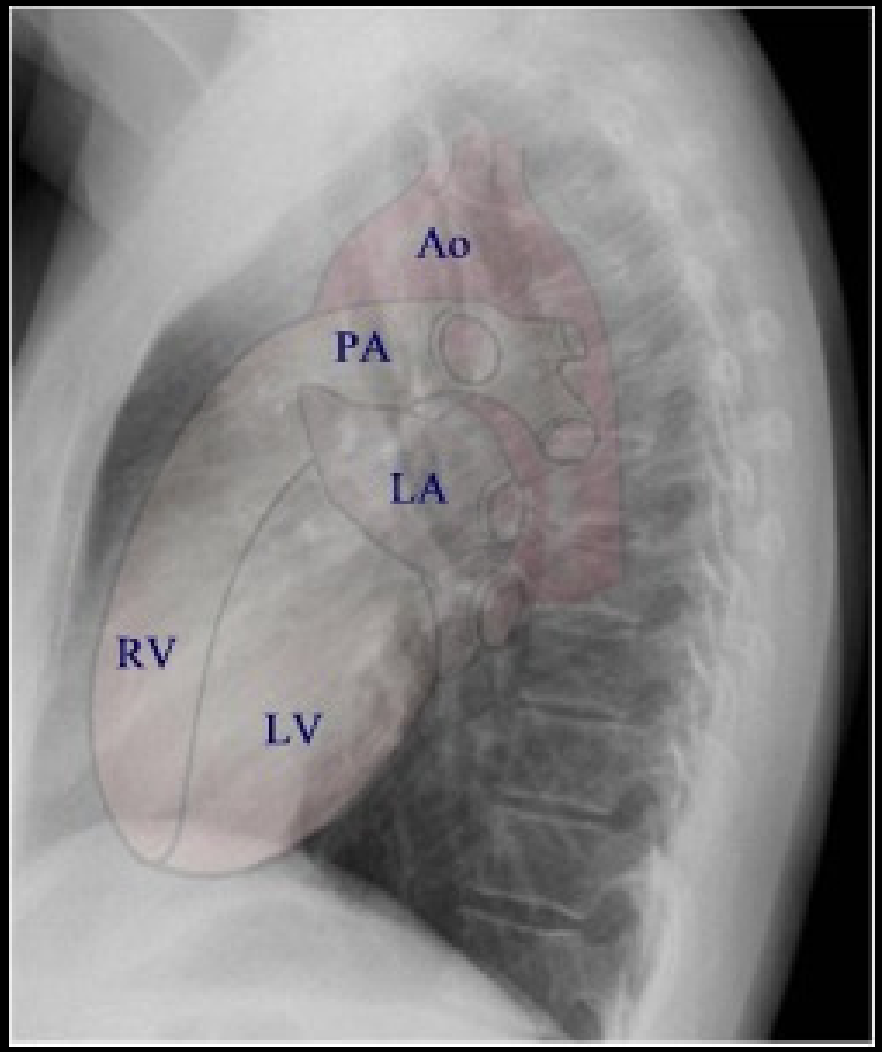
Ao
PA
LA
RV
LV

Pravý lalok

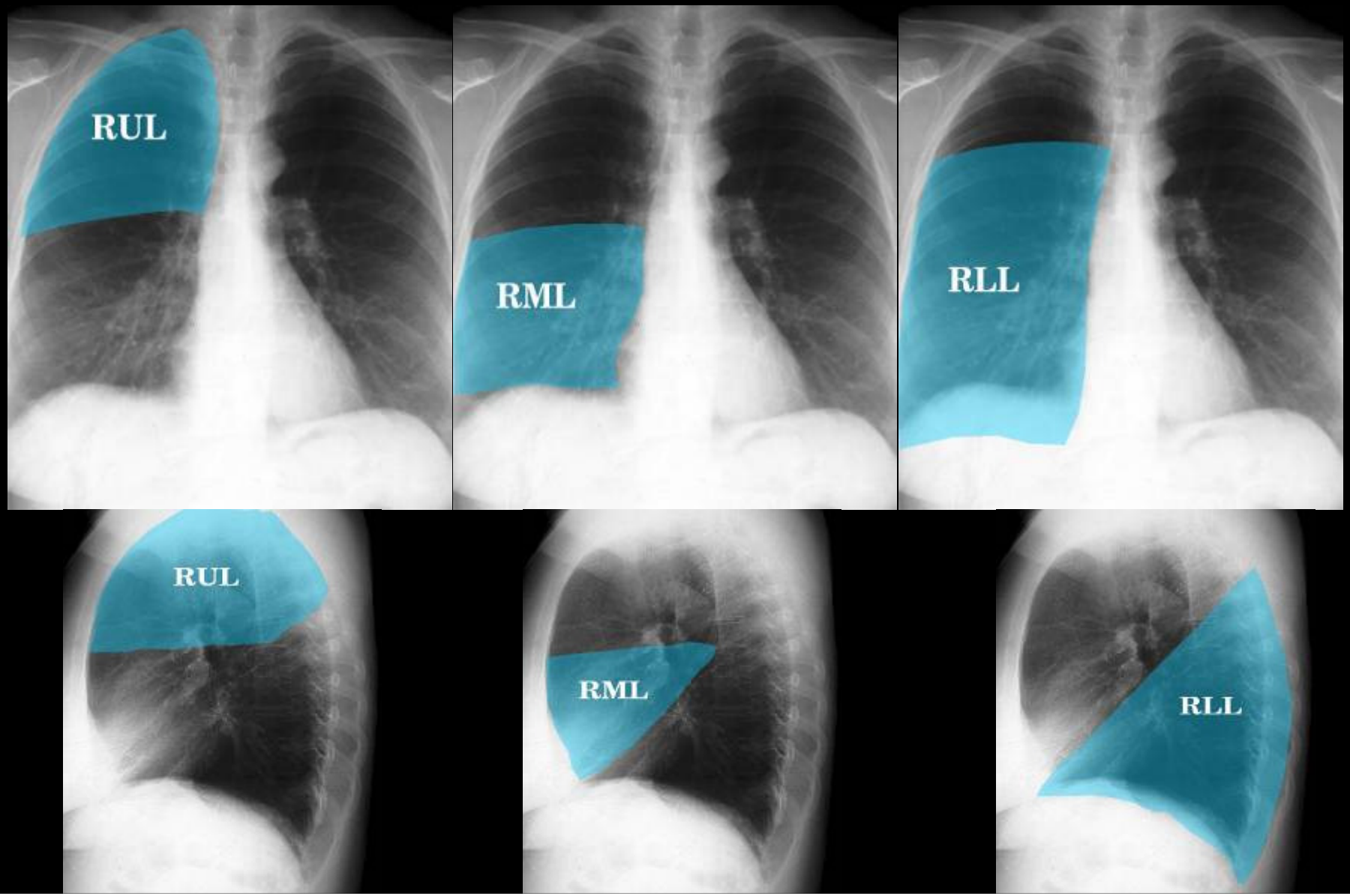

Levý lalok

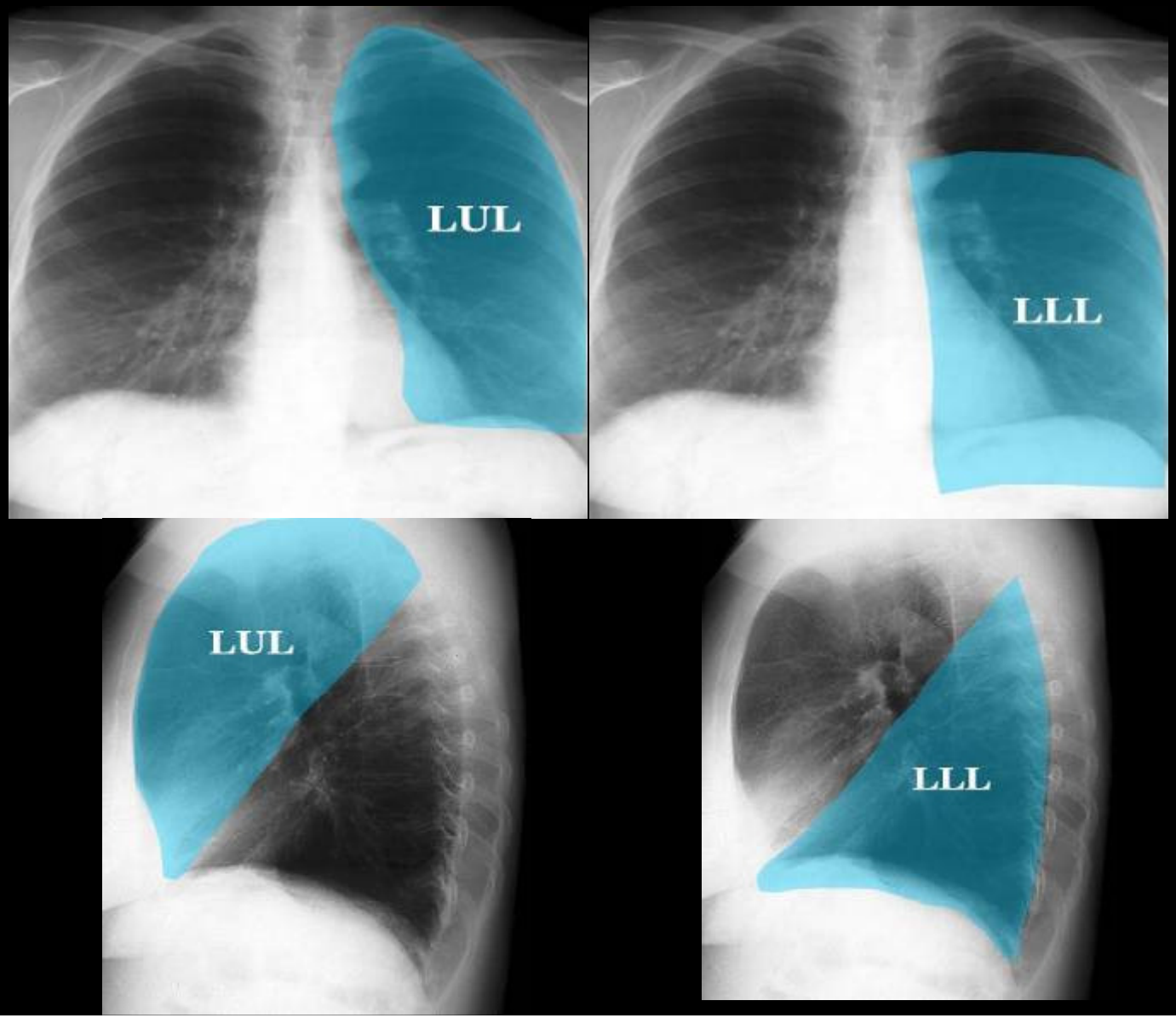

Anatomie končetiny

SIN
SIN

Sin

DX

XCI

IDx

Radiologická anatomie břicho, pánev

Snímek břicha vleže – nativní nefrogram

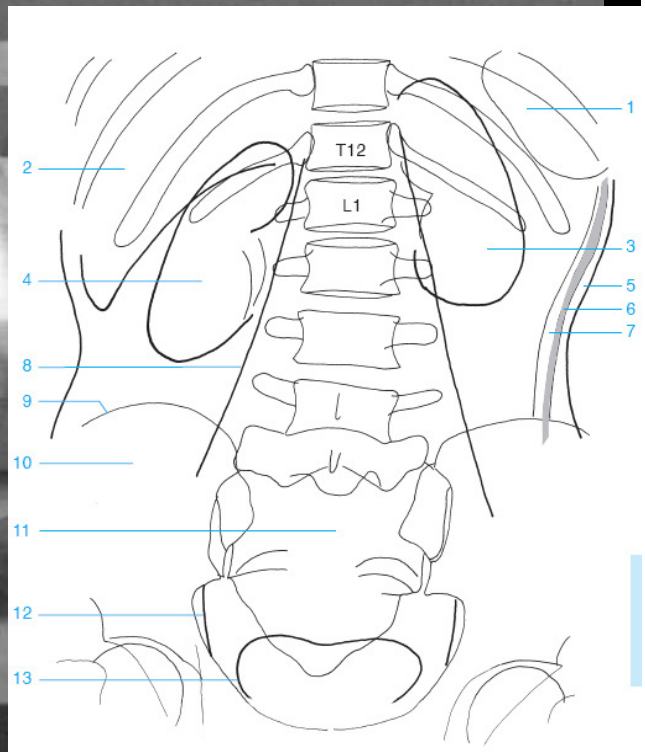

1 Spleen
2 Liver
3 Left kidney
4 Right kidney
5 Subcutaneous fat
6 Abdominal muscles
7 Preperitoneal fat
8 Psoas
9 Iliac crest
10 Ilium
11 Sacrum
12 Obturator internus
13 Urinary bladder

Nativní snímek břicha vestoje

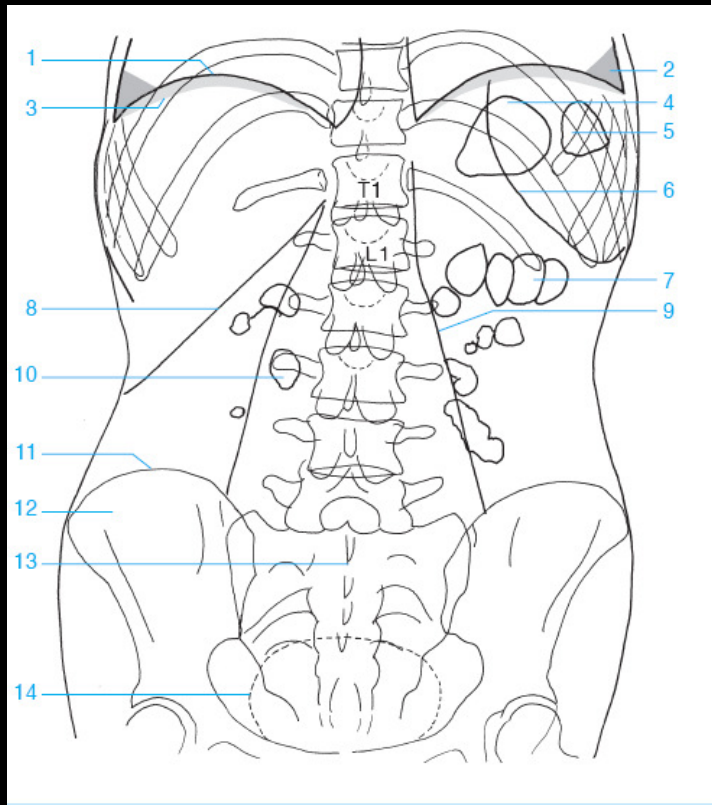

1 Diaphragm
2 Costodiaphragmatic recess (costophrenic angle)
3 Subphrenic space
4 Gastric bubble
5 Gas in the splenic flexure of the colon
6 Lower margin of the spleen
7 Gas in the transverse colon
8 Inferior margin of the liver
9 Margin of the psoas
10 Gas in the small bowel
11 Iliac crest
12 Ilium
13 Sacrum
14 Urinary bladder

Kontrastní vyšetření



apy	Antrum pyloricum	fdi	Flexura duodeni inferior
bd	Bulbus duodeni	fdj	Flexura duodenojejunalis
c	Costa	fds	Flexura duodeni superior
cga	Corpus gastricum	fg	Fundus gastricus
cgma	Curvatura gastrica major	ia	Incisura angularis
cgmi	Curvatura gastrica minor	ile	Ileum
D 1	Pars superior duodeni	je	Jejunum
D 2	Pars descendens duodeni	py	Pylorus
D 3	Pars horizontalis duodeni	Th 12	Vertebra thoracica XII.
D 4	Pars ascendens duodeni	v	Vertebra
dia	Diaphragma		

Žaludek

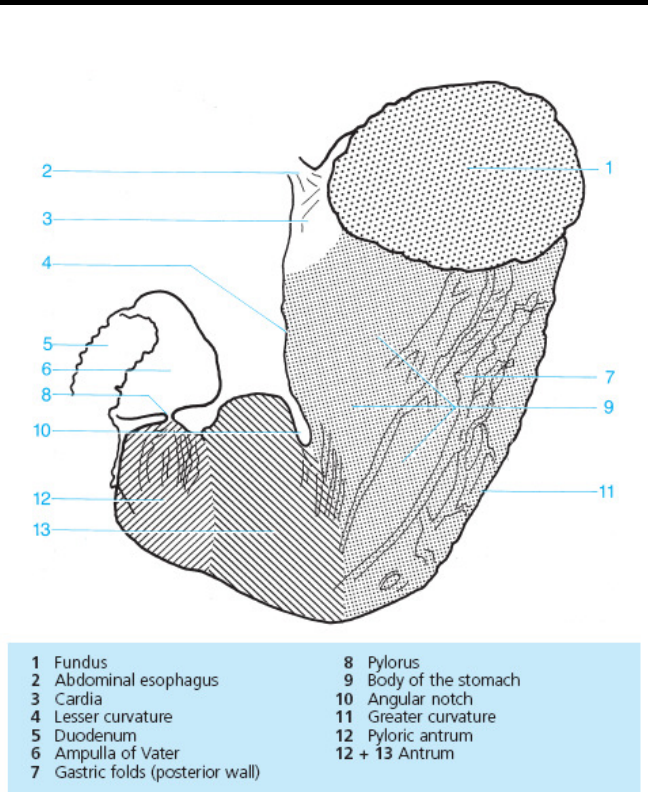
1
2
3
4
5
6
7
8
9
10
11
12
13
1 Fundus
2 Abdominal esophagus
3 Cardia
4 Lesser curvature
5 Duodenum
6 Ampulla of Vater
7 Gastric folds (posterior wall)
8 Pylorus
9 Body of the stomach
10 Angular notch
11 Greater curvature
12 Pyloric antrum
12 + 13 Antrum

Enteroclysis

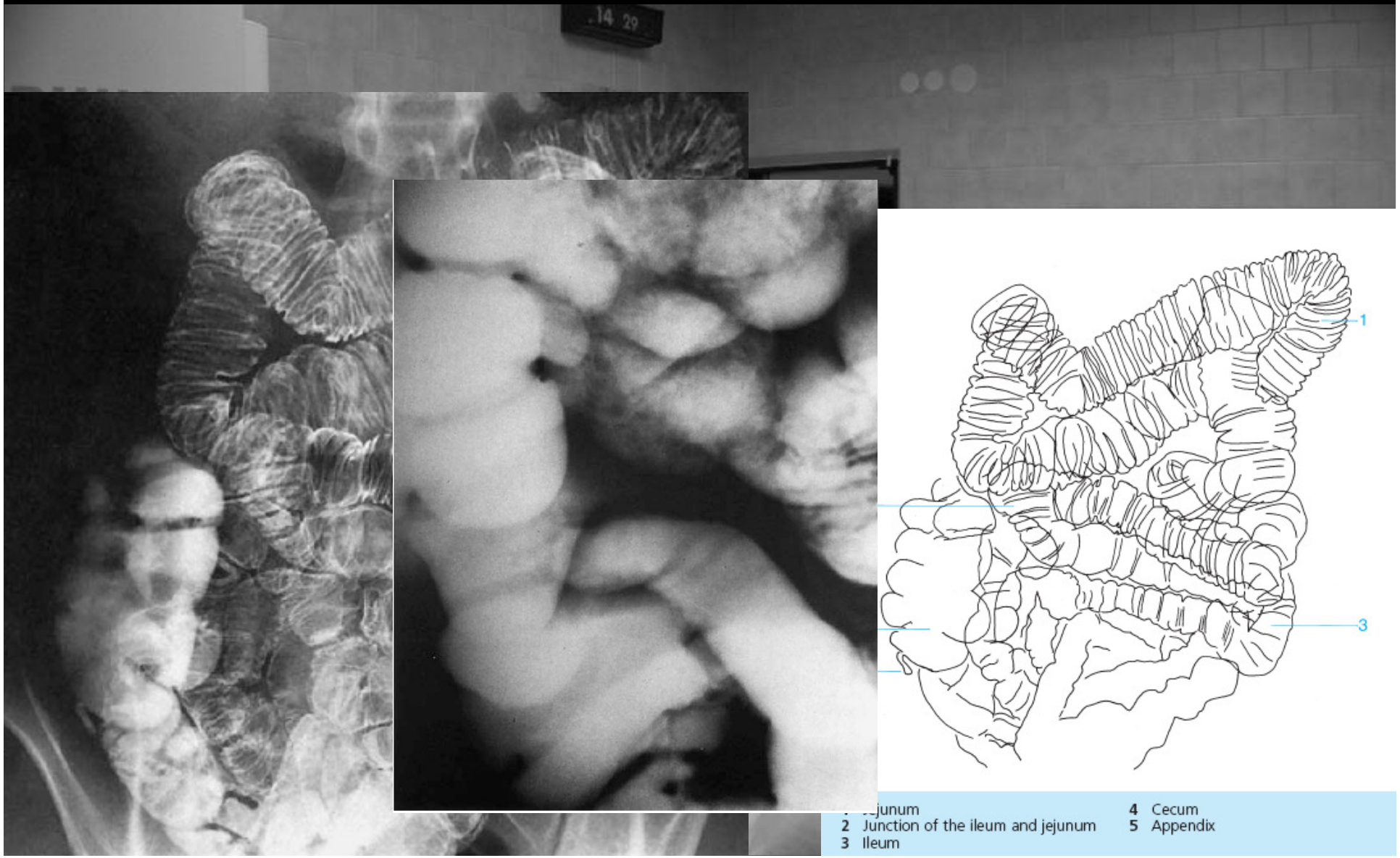

Irrigografie

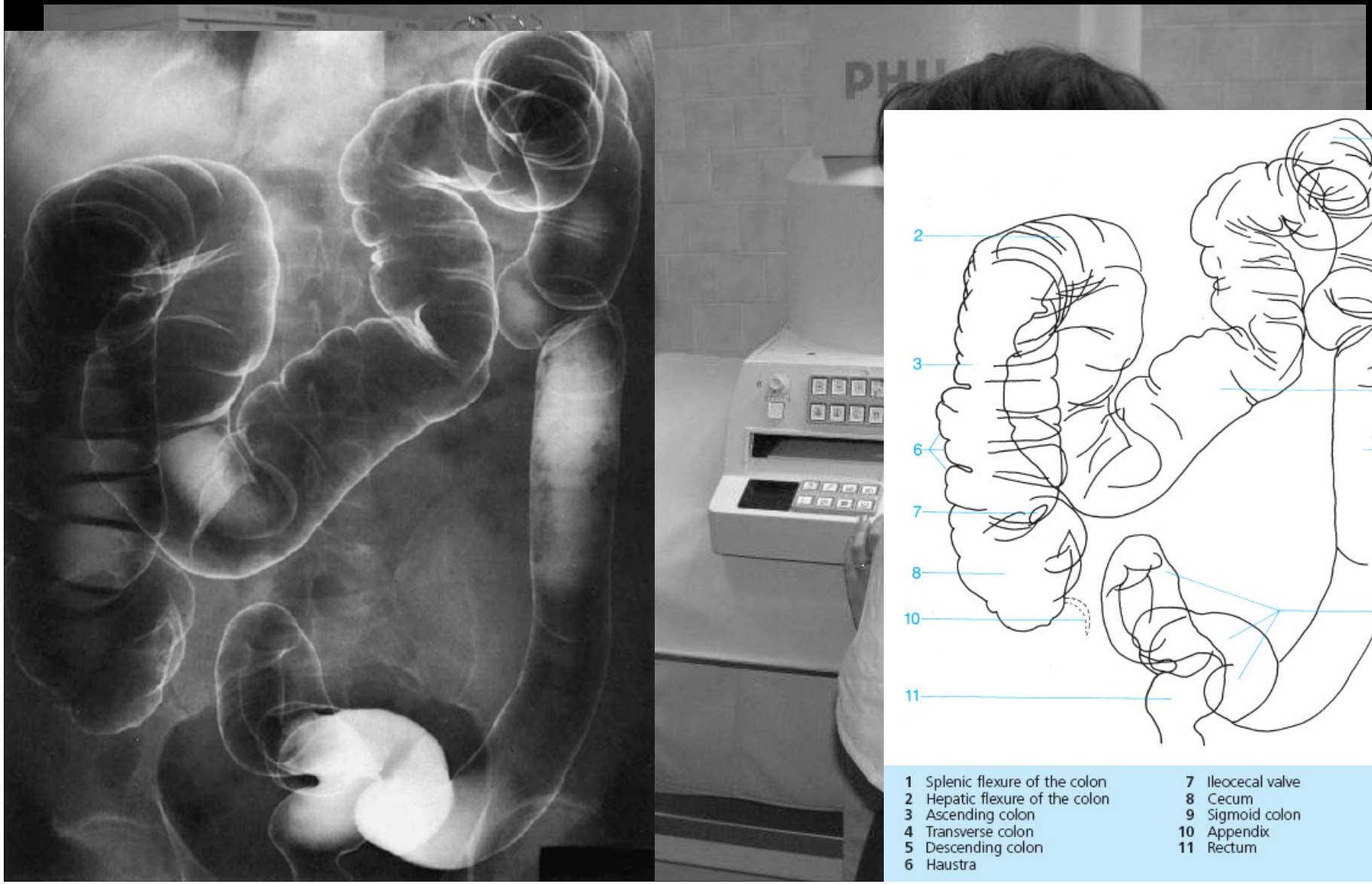

1 Splenic flexure of the colon
2 Hepatic flexure of the colon
3 Ascending colon
4 Transverse colon
5 Descending colon
6 Haustra
7 Ileocecal valve
8 Cecum
9 Sigmoid colon
10 Appendix
11 Rectum

í urografie

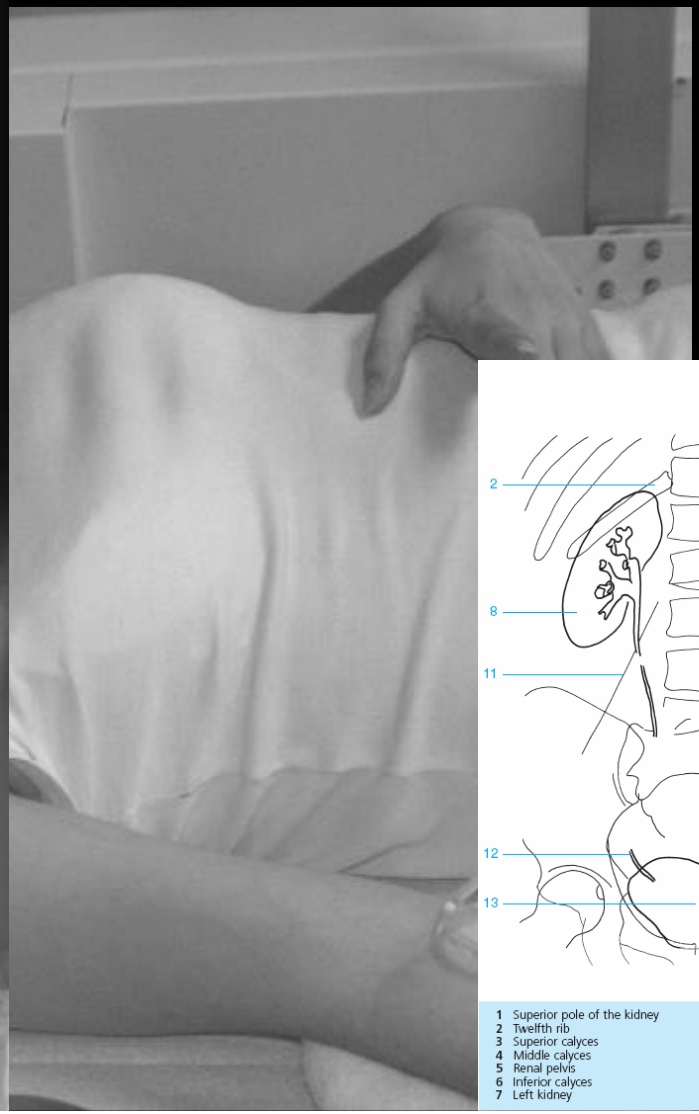

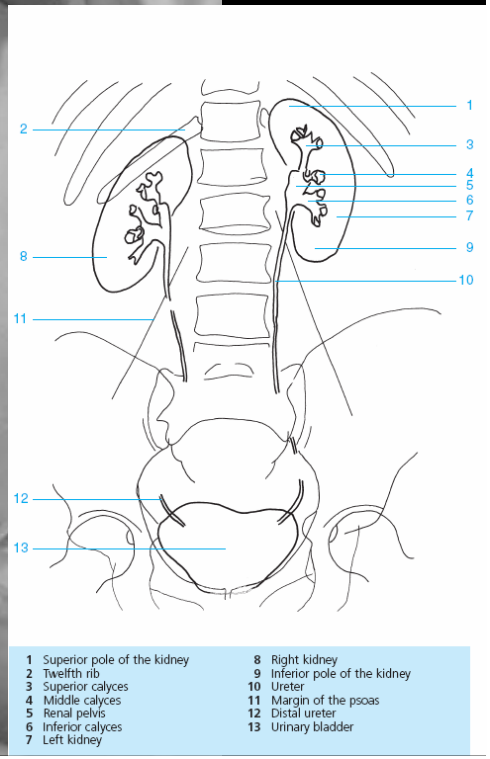

1 Superior pole of the kidney
2 Twelfth rib
3 Superior calyces
4 Middle calyces
5 Renal pelvis
6 Inferior calyces
7 Left kidney
8 Right kidney
9 Inferior pole of the kidney
10 Ureter
11 Margin of the psoas
12 Distal ureter
13 Urinary bladder

Hysterosalpingografie

1 Fundus of the uterus
2 Uterine ostium of the fallopian tube
3 Fallopian tube
4 Uterine cavity
5 Cervical canal
6 Fimbriae of the fallopian tube
7 Vagina
8 Instrument

ERCP

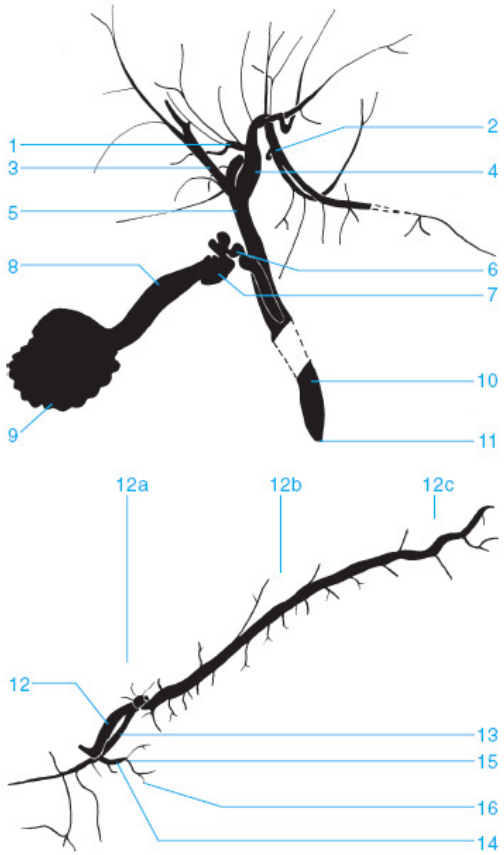

1 Medial branch of the left hepatic duct
2 Lateral branch
3 Right hepatic duct
4 Left hepatic duct
5 Common hepatic duct
6 Cystic duct
7 Neck of the gallbladder
8 Body of the gallbladder
9 Fundus of the gallbladder
10 Common bile duct
11 Papilla of Vater
12 Pancreatic duct
a Head region
b Body region
c Tail region
13 Accessory pancreatic duct
14 Primary lateral duct
15 Secondary lateral duct
16 Tertiary lateral duct